

The ameliorative impacts of wheat germ oil against ethanol-induced gastric ulcers: involvement of anti-inflammatory, antiapoptotic, and antioxidant activities

Rabab Shaban El-shafey¹, Samar H. Baloza², Lina Abdelhady Mohammed³, Hend Elsayed Nasr³, Mohamed Mohamed Soliman^{4*}, Heba I. Ghamry⁵, Salwa A. Elgendy⁶

¹Department of Forensic Medicine & Clinical Toxicology, Faculty of Medicine, Benha University, Benha 13511, Egypt,

²Genetic and Genetic Engineering, Animal Wealth Development Department, Faculty of Veterinary Medicine, Benha University, Benha 13736, Egypt,

³Department of Medical Biochemistry and Molecular Biology, College of Medicine, Benha University, Benha 13511, Egypt,

⁴Clinical Laboratory Sciences Department, Turabah University College, Taif University, PO Box 11099, Taif 21944, Taif, Saudi Arabia,

⁵Department of Home Economics, College of Home Economics, King Khalid University, P.O. Box 960, Abha, 61421, Saudi Arabia,

⁶Department of Pharmacology, Faculty of Medicine, Benha University, Benha 13511, Egypt

*Corresponding author: Clinical Laboratory Sciences Department, Turabah University College, Taif University, Taif, Saudi Arabia. Email: mmsoliman@tu.edu.sa

This study examined if wheat germ oil (WGO) has gastroprotective impacts against ethanol-induced gastric ulcer in rats. Rats were assigned into control, WGO, ethanol, omeprazole + ethanol, and WGO + ethanol. WGO prevented gastric ulceration and damage induced by ethanol, the same effect induced by omeprazole, a widely known medication used for gastric ulcer treatment. WGO reduced gastric ulcer index, nitric oxide, and malondialdehyde levels in the stomach. WGO boosted the expression of nuclear factor erythroid 2-related factor 2 (Nrf2), heme oxygenase-1 (HO-1), Bcl2, and the antioxidants. WGO showed inflammatory and anti-inflammatory impacts through the control of interleukin (IL)-1 β , Tumor necrosis factor alpha (TNF- α), and IL-10 that were altered in ethanol-administered rats. Ethanol up-regulated caspase-3 and nuclear factor-kappa B (NF-kB) expression and showed histopathological changes such as necrosis and mucosal degeneration that were mitigated by pre-administration of WGO. Moreover, WGO decreased gastric immunoreactivity of NF-kB and increased transforming growth factor beta-1 (TGF- β 1) that were associated with upregulation of Nrf2, heme oxygenase-1 (HO-1), and antioxidant expression and production. In conclusion, WGO reduced ethanol-induced stomach toxicity by regulating genes involved in oxidative stress, inflammation, and apoptotic/antiapoptotic pathways.

Key words: ethanol; gastric ulcers; mRNA gene expression; Nrf2/HO-1 signaling pathway; oxidative stress; wheat germ oil.

1. Introduction

Gastric ulcer (GU) is a major biohazard that threatens human health.¹ Globally, GU affects 14.5 million people, with 4.08 million deaths occurring each year.² GU is induced by a digestive system imbalance among aggressive substances like refluxed bile salts, and acid, pepsin as well as consumed medicines, and protective elements such as the surface epithelial cells and the mucus bicarbonate barrier.³ Other variables, such as stress, smoking, and alcoholism, as well as gastric ulcers of various forms have been related to the overuse of non-steroidal anti-inflammatory drugs (NSAIDs).⁴ The majority of commercially available medications, such as omeprazole and other antiacids, have poor efficacy in treating gastrointestinal diseases and are frequently linked with substantial side effects.⁵

According to previous studies, the average yearly alcohol intake for people is around 10 L, with males

consuming approximately 14 L.⁶ Furthermore, current medical study has found that the drinking population has a substantially higher frequency of gastrointestinal issues than the nondrinking population. Frequent consumption of high-concentration alcohol causes epithelial cell necrosis and detachment, gastric mucosal thinning, injury and embolism in the microvascular endothelium, and ischemic and anoxic tissue damage, resulting in gastric mucosal deterioration and ulcer formation, as well as gastroduodenal mucosal injury and related gastropathy.⁷ When alcohol enters the stomach mucosa, oxygen-free radicals, active oxidation metabolites such as protease, and superoxide anion (O₂) are released, as well as sticking to the endothelium of the vasculature, resulting in vascular blockage and mucosal damage.⁸ Alcohol causes stomach mucosal injury, and in this process, the role of free radicals is crucial. In the gastric mucosa of chronic drinkers,

there are higher quantities of lipid peroxides and free radicals.⁷

One of the most extensively utilized experimental models is the ethanol-induced acute GU model.⁹ Compared to other GU methods, the ethanol-induced GU model has an advantage, in that it closely reflects the symptoms of acute clinical peptic ulcer disease.¹⁰ Alcohol consumption has long been known to cause inflammation of the gastric mucosa. Ethanol penetrates the gastrointestinal mucosa quickly after administration, producing membrane disruption, erosion, and cell exfoliation. As a result of these actions, necrosis and ulcer development can occur by increasing mucosal permeability to stomach acid and the production of vasoactive substances by macrophages, mast cells, and blood cells.¹¹ Ethanol also causes microvascular damage by lowering cellular antioxidant levels while decreasing blood flow and increasing the generation of pro-inflammatory cytokines and reactive oxygen species (ROS).¹⁰ The most commonly prescribed medications for treating and preventing stomach ulcers include proton pump inhibitors (like omeprazole, lansoprazole), antacids, cell protection factors, and H₂ receptor blockers (such as cimetidine, ranitidine). Because these medications induce impotence, arrhythmia, hematological changes, hypersensitivity, and gynecomastia, they should be avoided. As a result, using a natural anti-ulcer drug with minimal side effects is unavoidable.¹²

As known, most commonly used drugs used for gastric ulcer treatment are inhibitors for proton pump, antacids, H₂-receptor antagonists, and anticholinergics.^{13,14} However, most of them have severe side effects that include irritability, changes in the hematopoietic system, and arrhythmia.¹⁵ Therefore, physicians search for alternate safe medication to cure gastric ulcer. Recent studies by Boutemine et al.^{16,16} have confirmed a safe herbal medication (*Pistacia lentiscus* L.) with potential therapeutic effects against both gastric ulcers¹⁶ and colitis¹⁷ through the regulations of inflammatory processes associated with these inflammatory diseases].

Wheat germ (WG) is a leftover from the flour milling process. During the milling process, the germ is separated from the bran and starch.^{18,19} The most significant part of the wheat is the germ, accounting for around 2.5% of the total weight and playing a vital role in food processing with high nutritional value.²⁰ Anti-inflammatory and antioxidant properties of tocopherols and phenol compounds are abundant in wheat germ oil (WGO), as indicated by decreased O₂ generation and NADPH oxidase activity.²¹ It also contains unsaturated fatty acids, including linoleic and linolenic acids and vitamin E, which protect oxidative processes in tissues.²² In a previous research, animals supplemented with an experimental diet containing 10% WGO showed a 9-week improvement in liver lesions produced by benzene injection.²³ This research aims to see if WGO can protect rats from developing Gus caused by ethanol, as well as the mechanisms involved.

2. Materials and methods

2.1 Medications and chemicals

Pharopharma Co. (Cairo, Egypt) provided omeprazole, and Sigma Chemical Co. supplied 100% ethanol (St Louis, MO, USA). WGO was provided by Egypt's El Captain Company (Cap Pharm). Sigma Aldrich (St Louis, Missouri, USA) provided the hematoxylin and eosin (H&E) staining solution. All of the compounds were pure powder and of molecular grade. QIAGEN (Valencia, CA, USA) provided the SYBR Green PCR Master Mix, Oligo dT primers, and Qiazol.

2.2 Animals

A total of 30 mature albino rats weighing 200–220 g were used (aged 2 months) were utilized for this research. The rats in this study were collected from the Pharmacology Department's house of animal breeding facilities at Benha University's Faculty of Medicine, Egypt. The rats were kept in clean and well-ventilated cages, and they had unlimited water and food supplies. The rats were kept in a scientific setting under strict control (25 °C, 60% humidity, and a 12 h/12 h light/dark cycle). Before any experimental procedures, the animals were given a week to acclimate and handled manually. The ethical rules for laboratory animal research were followed during all animal-related procedures, which the ethics committees of Benha University and Taif University (TURSP-2020-09) approved.

2.3 Animal grouping, treatments, and samplings

Thirty adult albino rats were divided into 5 groups, each with 6 animals as following:

2.3.1 Group I (negative control group)

These animals were gavage with saline and allowed free access to food and water without any medications to assess the basic parameters.

2.3.2 Group II (positive control or WGO group)

These animals received WGO (1.5 mL/kg) (~about 1,400 mg/kg) orally, once daily²⁴ for consecutive 10 days.

2.3.3 Group III (ethanolic group)

Animals of this group were treated with only absolute ethanol (5 mL/kg) orally, once daily for consecutive 10 days.²⁵

The time used (10 days) is the optimal to show a high grade of gastric ulceration and amelioration by WGO as stated by previous reports.^{24,25} The introduction of 100% ethanol alcohol to the stomach caused gastric mucosal damage (5 mL/kg i.e. 1 mL/rat) via orogastric intubation for 10 consecutive days.²⁵ To avoid eating stool, which interferes with the development of stomach damage. The rats were kept in metabolic cages with extensive mesh flooring and high ceilings.²⁶

2.3.4 Group IV: standard group (omeprazole + ethanol)

At a dose of 20 mg/kg, omeprazole was given orally to the animals in this group²⁵ followed by absolute ethanol (5 mL/kg) orally, 1 h later, once daily for consecutive 10 days.

2.3.5 Group V (WGO + ethanol)

Animals of this group were treated with WGO (1.5 mL/kg) orally, once daily²⁴ followed by absolute ethanol (5 mL/kg) orally, 1 h later, every day for 10 consecutive days, and the animals were scarified 1 h later at the conclusion of the research.²⁵ Rats were sedated for 2–5 min with a cotton pad saturated with diethyl ether in a desiccator at the end of the experiment, then scarified, and killed by cervical dislocation. Blood was drawn through a heart puncture and centrifuged at 3,000 rpm for 10 min to extract clear serum, which was then kept at –20 °C until analysis. Simultaneously, the gastric tissues were soon removed, and along the greater curve of the stomach, it was opened, and volume and pH measurements were taken of their contents. Following that, before being evaluated macroscopically for the gastric ulcer index (GUI), stomach tissue specimens were cleansed with a physiological saline solution to remove any thrombus.^{27,28}

Next, the stomach tissue homogenate was divided into 3 sections, promptly frozen, and stored at 80 °C for malondialdehyde (MDA) and NO determinations. The second portion was kept in Qiazol for future mRNA expression of nuclear factor erythroid 2-related factor 2 (Nrf2), heme oxygenase-1 (HO-1), caspase-3 (case-3), and antiapoptotic Bcl-2 gastric genes. The third part was embedded in 10% formalin for histological and immunohistochemical testing.

2.4 Measurement of gastric juice volume and pH

The stomach contents were collected in a centrifuge and spun for 8 min at 5,000 rpm. The supernatant fluid was titrated with a 0.1 mM NaOH solution to evaluate stomach pH.²⁹

2.5 GUI and percentage of ulcer preventive index

Takagi and Okabe³⁰ techniques were used to determine the gastric ulcer index (GUI, mm²) and the percentage of ulcer preventive index (PI). With a ruler and a 10× magnifying lens, the ulcerated surface area was measured first and then the severity of the ulcer was determined as specified in Table 1. The UI and ulcer PI percentages were then computed using the formulae below.²⁷

Estimation of GUI was done as following formula:

$$\text{GUI} = \frac{\text{sum of lesion areas in each group}}{\text{total stomach area}} \times 100$$

After that, the percentage of ulcer prevention index was calculated using the following equation:

$$\text{Ulcer PI} = \frac{\text{UI of ethanolic group} - \text{UI of pretreated group}}{\text{UI of ethanolic group}} \times 100$$

2.6 Antioxidants and cytokine assays

To measure MDA, reduced glutathione (GSH), and catalase (CAT), levels, enzyme-linked immunosorbent assay

Table 1. Gastric ulcer scoring system based on the severity of the ulcer.

Ulcer score	Gastric lesion
0	No lesion
1	Mucosal edema and petechiae
2	1–5 small lesions (1–2 mm)
3	More than 5 small lesions or 1 intermediate lesion (3–4 mm)
4	Two to more intermediate lesions or 1 gross lesion (>4 mm)
5	Perforated ulcers

(ELISA) kits were purchased from Life Span Biosciences Company (LS.Bio), North America for MDA and Shanghai Blue Gene Biotech CO., LTD for GSH and CAT in accordance with the manufacturer's recommendations.

Serum levels of interleukin-1 (IL-1) and tumor necrosis factor alpha were estimated using specific ELISA (ab255730 and ab46070, respectively) kits and spectrophotometric analysis according to the kits' instructions. IL-10 was measured using commercial kit obtained from Abcam, USA (Rat IL-10 ELISA Kit, ab100765). Data obtained from ELISA reader were calculated as described in the kit instructions.

2.7 Measurement of MDA and NO in gastric tissue homogenate

To measure gastric MDA and NO, gastric tissue was homogenized as described before.³¹ On a calibrated scale, 1 g of stomach tissue was weighed, then 9 mL of PBS buffer was added, and the mixture was mixed with ice. Ice was utilized to avoid protein degradation and limit enzyme activity and deactivation inside the tissue during homogenization. Using a chilled centrifuge, the homogenous mixture was centrifuged for 20 min in the falcon tube at 12,000g at 4 °C. The sediment was discarded while the supernatant was collected. The supernatants were separated into microtubes and stored at 20 °C until NO and MDA levels were measured.

The nitrite generated by nitric oxide (NO) oxidation was used to determine the content of NO³², which was based on the Griess diazotization technique. MDA was measured by creating a 1:2 adduct with the amino group of thiobarbituric acid, which absorbed significantly at 532 nm.³³

2.8 Quantification of oxidative stress, apoptotic, and antiapoptotic markers in gastric tissues by quantitative real-time polymerase chain reaction

The 7500 Fast is a high-performance system. Quantitative real-time polymerase chain reaction (qRT-PCR) for nuclear factor erythroid 2-related factor-2 (Nrf2), heme oxygenase-1 (HO-1), and caspase-3 (casp3) was performed using RT-PCR equipment, and antiapoptotic Bcl-2 genes utilizing 5'-Oligonucleotide-3' primer sequences for each gene (Table 2) (Applied Biosystems, CA). Stomachs from all rat groups were collected and immediately frozen at –80 °C: control, WGO, ethanolic

Table 2. Oligo sequences for used quantitative RT-PCR primers.

SYBR Green RT-PCR primers	5'-Oligo sequences-3'	Accession number	Product size (bp)
qR-Nrf2	F: TTGTAGATGACCATGAGTC R: TGTCTGTGTATGCTGCT	NM_031789.2	141 bp
qR-HO-1	F: GTAAATGCAGTGTGGCCC R: ATGTGCCAGGCATCTCCTTC	NM_012580.2	178 bp
qR-casp3	F: GAGCTTGGAAACGGAAGAAA R: TAACCGGTGCGGTAGAGTA	NM_012922	122 bp
qR-Bcl2	F: ACTCTTCAGGGATGGGGTGA R: TGACATCTCCCTGTTGACGC	NM_016993	94 bp
qR- β actin	F: AAGTGTGACGTTGACATCCG R: TCTGCATCCTGTCAGCAATG	NM_031144	71 bp

The sequences of rat primers; qR-Nrf2, nuclear factor erythroid 2-related factor 2 (Nrf2); qR-HO-1, hemoxygenase-1; qR-casp3, caspase-3; qR-Bcl2, antiapoptotic Bcl-2, and β -actin was selected as the reference gene.

(Omeprazole+ ethanol), and (WGO+ ethanol). Total RNA from 50 mg of stomach tissue was separated with Trizol reagents (Thermo Fisher Scientific, Inc., Waltham, MA, USA) and stored at 80 °C per the guidelines provided by the manufacturer. The absorbance at 260/280 nm of all specimens ranged between 1.8 and 2.1, showing that the RNA quantity and quality were both excellent (BMG LAB TECH, GmbH, Germany). A predetermined amount of RNA (1,000 ng) was transcribed backwards into cDNA using the High-Capacity cDNA Reverse Transcription Master Mix (Applied Biosystems, USA) procedure at 25 °C for 10 min, 37 °C for 120 min, and 85 °C for 5 min. Until the gene expression analysis, cDNA samples were kept at -80 °C. 1.5 μ L of 1 μ g/L cDNA, 10 μ L SYBR Green PCR Master Mix (QuantiTect SYBR Green PCR Kit, Qiagen), 1 μ M of each forward and reverse primers for each gene nuclease-free water to a final volume of 20 μ L qRT-PCR were adjusted with heating at 95 °C for 10 min, then 40 cycles of denaturation at 95 °C for 15 s, annealing, and extension at 60 °C for 1 min. Each sample's cycle threshold (Ct) values were established. The Ct value of the target gene mRNA was adjusted to the internal reference gene, β -actin. The expression values for the gastric samples were quantified with a formula: $2^{-\Delta\Delta CT}$ ³⁴ using the 1-way analysis of variance (ANOVA) test (SPSS17.0 software), to calculate the mean \pm SE of fold change in the term of the target genes in the gastric tissue of experimental groups.

2.9 Histological and immunohistochemical analyses

For 48 h, stomach specimens were fixed in 10% buffered formalin. Before being chopped into 5 μ m length, the samples were dehydrated before being embedded in paraffin wax after being dehydrated in a graded alcohol solution. H&E staining were used to finish the samples. The histological alterations in the stomach tissues were examined using an optical microscope³⁵.

The manufacturer's instructions were followed when investigating the phosphonuclear factor kappa light chain enhancer of activated B cells p65 in stomach tissue using the impress excel staining kit (cat# MP-7601; Vector Laboratories, Burlingame, CA, USA). Antigen retrieval

was achieved by boiling the sections in citrate buffer after they had been deparaffinized and hydrated for 30 min at 95 °C (10 mM, pH 6). Anti-p-NF-kB p65 (sc-33039) primary antibodies were used at a 1:50 dilution in Tris-buffered saline to incubate the sections overnight (TBS). Before being counterstained with hematoxylin, sections were further treated with a secondary antibody. The percentage of immunologically positive regions was calculated using the "Image J" tool.³⁶ TGF- β 1 immunoreactivity was determined by incubating sections overnight at 4 °C with a primary antibody against TGF- β 1 (cat. no. ab92486; Abcam; dilution 1:150). The slices were treated for 1 h with the biotinylated antibody and then incubated in Elite ABC reagent after 3 PBS washes (Vector Laboratories). Following that, the slices were stained with 3,3-diaminobenzidine (DAB, Sigma-Aldrich; Merck KGaA).³⁷

2.10 Statistical analysis

The acquired data were tallied and examined utilizing computer software (SPSS, Version 26 for Windows, SPSS Inc., Chicago, IL). The information was presented in the form of a mean and standard deviation. RT-PCR was expressed as mean \pm SE. The Shapiro-Wilk test was performed to assess normalcy, assuming normality $P < 0.05$. To discover differences between normally distributed data, the 1-way ANOVA test was used. A significant ANOVA test was used to detect significant pairings, followed by post hoc Tuckey HSD multiple comparisons using the Bonferroni test. This investigation's acceptable threshold of significance was $P < 0.05$.

3. Results

3.1 Effect of WGO pretreatment on gastric ulcer assessment (gastric juice volume, gastric pH, ulcer index, and percentage of ulcer PI)

Table 3 demonstrates that the significant findings of the absolute ethanol that led to reduction in the gastric pH within the ethanolic group corresponding with a considerable rise in stomach juice volume ($P < 0.05$) compared to normal control group rats. The explanation for the largest number of ulcer index in ethanolic rats

Table 3. Protective effect of WGO on ethanol-induced changes on gastric juice volume (mL), pH, ulcer index (mm²), and PI (%).

	Control	WGO	Ethanol group	Omeprazole + ethanol group	WGO + ethanol group
Gastric juice volume (mL)	1.5 ^a ± 0.1	1.6 ^a ± 0.2	3.1 ^b ± 0.1	1.6 ^a ± 0.1	2.02 ^d ± 0.1
Gastric pH	6.4 ^a ± 0.1	6.5 ^a ± 0.1	2.6 ^b ± 0.3	8.7 ^c ± 0.4	4.7 ^d ± 0.1
Ulcer index (mm ²)	0 ^a ± 0.00	0 ^a ± 0.0	5.1 ^b ± 0.01	1.4 ^c ± 0.1	2.4 ^d ± 0.1
Ulcer PI (%)	–	–	0	72.6	51.5

Values are means ± SD for 6 different rats per treatment. Values with different letters are statistically different at $P < 0.05$. SD, standard deviation.

Table 4. Protective effect of WGO on ethanol-induced systematic oxidative stress and changes on serum antioxidants.

	Control	WGO	Ethanol groups	Omeprazole + ethanol group	WGO + ethanol group
Serum MDA (ng/mL)	14.2 ^a ± 1.2	13.4 ^a ± 1.3	39.4 ^b ± 1.8	24.7 ^c ± 1.8	17.9 ^d ± 2.7
Serum GSH (pg/mL)	138.3 ^a ± 8.0	146.8 ^a ± 5.1	5.6 ^b ± 3.6	1.6 ^c ± 2.0	112.9 ^d ± 6.9
Serum catalase (pg/mL)	71.6 ^a ± 2.4	76.3 ^a ± 3.4	3.3 ^b ± 4.5	49.1 ^c ± 2.8	59.5 ^d ± 4.0

Values are means ± SD for 6 different rats per treatment. Values with different letters are statistically different at $P < 0.05$. SD, standard deviation.

was pH = 2.6. In contrast to the ethanolic group, pre-administration with WGO or omeprazole 20 mg/kg for 10 days resulted in a substantial increase in stomach pH (4.7 and 8.7, respectively), as well as a decline in the volume of gastric juice and GUI ($P < 0.05$). Pretreatment with WGO or omeprazole showed significant increase in percentage of ulcer PI (51.50% and 72.67%, respectively) comparing with ethanolic group.

3.2 Macroscopic examination of stomach tissues after ethanol administration in rats

As seen in Fig. 1A and B, control and WGO-administered rats show normal gastric mucosa without ulceration. Compared to control groups, oral ethanol administration resulted in severe stomach ulcers with significant apparent hemorrhagic erosion, leading to high UI (Fig. 1C). Pretreatment with WGO or omeprazole for 10 days, significantly prevented severe stomach mucosal damage caused by ethanol, as demonstrated in Fig. 1D and E.

3.3 Effect of WGO pretreatment on serum levels of oxidative stress markers altered by ethanol in rats

Compared to the normal control groups, ethanol-induced GU was related to a rise in MDA ($P < 0.05$) and a reduction in CAT and GSH. Pretreatment with WGO or omeprazole ameliorated such changes in MDA ($P < 0.05$), CAT, and GSH. WGO restored the alterations induced by ethanol and reversed to nearly the normal control levels (Table 4).

3.4 Impact of WGO against ethanol-induced changes on gastric tissue MDA and NO

Table 5 shows that ethanol-induced gastric ulcers resulted in a considerable rise in gastric MDA compared to regular control groups. The standard group (omeprazole) had significantly lowered MDA levels ($P < 0.05$). MDA levels were lowered in rats pretreated with WGO compared with ethanolic rats ($P < 0.05$). Furthermore, the amount of stomach tissue NO in the ethanolic group was considerably lower than the standard control groups. Pretreatment with WGO or omeprazole resulted in a

substantial rise in stomach NO ($P < 0.05$) as compared to the ethanolic group, but not close to the usual control level as shown in Table 5.

3.5 Effect of WGO pretreatment on serum levels of pro-inflammatory (TNF- α , IL-1 β) and anti-inflammatory (IL-10) cytokines in ethanol-induced gastric ulcer in rats

When compared to the traditional control groups, ethanol-induced GU was validated by an elevation in the production of pro-inflammatory cytokines (TNF- α , IL-1 β) and a decrease in the anti-inflammatory cytokine IL-10. Pretreatment with WGO or omeprazole resulted in a substantial drop in TNF- α , IL-1 β ($P < 0.05$) with an increase in IL-10 (Table 6), confirming the role of WGO in such modulation. The IL1/IL10 and TNF/IL10 ratio was examined as shown in Fig. 6. It showed a significant increase in ethanol-administered group that was significantly ameliorated in omeprazole and WGO receiving groups. This confirms the potential of WGO as anti-inflammatory agent directed against ethanol-induced GU.

3.6 Effect of WGO pretreatment on oxidative stress, apoptotic, and antiapoptotic markers altered in ethanol-administered rats

The ethanol-administered group had a considerable downregulation of transcription factor Nrf2 and its downstream HO-1 expression compared to the control group, as shown by RT-PCR (Fig. 2A and B). In addition, the induction of apoptosis by ethanol was validated by a considerable increase in caspase-3 expression and a reduction in the antiapoptotic Bcl-2 gene ($P < 0.05$, Fig. 3A and B, respectively). Pretreatment with WGO or omeprazole inhibited the ethanol-provoked gastric ulcer, as WGO displayed upregulation of Nrf2, HO-1, and Bcl-2 and downregulation of caspase-3 mRNA expression (Figs 2 and 3).

3.7 Histopathology examination

The stomach tissues of group control and WGO were microscopically examined and demonstrated normal




Fig. 1. Photographs depicting the morphology of the rat stomach upon necropsy. The animals in the control group (A) and the WGO group (B) did not have any obvious lesions. In comparison with the control group, the ethanolic group (C) had a severe lesion in the gastrointestinal mucosa. Omeprazole + ethanol group 20 mg/kg (D) and WGO+ ethanol 1,400 mg/kg (E) showed mild gastric lesions. Yellow arrows indicate gastric lesion.

Table 5. Protective effect of WGO on ethanol-induced changes on gastric tissue oxidative stress markers.

	Control	WGO	Ethanolic groups	Omeprazole + ethanol group	WGO + ethanol group
Tissue MDA (nmol/g tissue)	78.1 ^a ± 5.6	71.5 ^a ± 7.7	161.5 ^b ± 4.3	11.1 ^c ± 6.7	91.1 ^d ± 5.1
Tissue NO (μmol/g tissue)	6.3 ^a ± 0.2	6.2 ^a ± 0.2	2.5 ^b ± 0.2	5.1 ^c ± 0.2	4.7 ^c ± 0.2

Values are means ± SD for 6 different rats per treatment. Values with different letters are statistically different at $P < 0.05$. SD, standard deviation.

intact gastric mucosa, normal gastric glands, inflammatory cell infiltration and no edema, hyperemia, or hemorrhage (Fig. 4A and B). The ethanolic group's stomach tissue had significant injury and necrosis of mucosal cells and serious bleeding, edema, and leukocyte infiltration (Fig. 4C). Mild deterioration and necrosis at the apex of mucosa tissue, limited edema, hemorrhage, and cell infiltration were observed after a 10-day pretreatment with WGO or omeprazole (Fig. 4D and E).

3.8 Immunohistochemical findings

The term of nuclear factor-kappa B (NF-κB) in the gastric epithelium of both the control and WGO groups was consistent (Fig. 5A and B) (brown color). Both groups' mean immune-stained area % of NF-κB did not change significantly (Fig. 5F). Ethanolic nontreated rats showed marked increased in NF-κB expression (Fig. 5C) with a substantial ($P < 0.05$) increase of the average immunoreactive stained area % compared with pretreated groups

Table 6. Protective effect of WGO on ethanol-induced changes on serum pro-inflammatory and anti-inflammatory cytokines levels.

	Control	WGO	Ethanolic groups	Omeprazole + ethanol group	WGO + ethanol group
Serum IL-1 β (pg/mL)	40 ^a \pm 3.5	33.3 ^a \pm 3.2	85.1 ^b \pm 7.5	56.6 ^c \pm 4.3	6.3 ^c \pm 2.1
Serum TNF- α (pg/mL)	151.3 ^a \pm 4.3	150 ^a \pm 6.4	301.5 ^b \pm 7.6	201.1 ^c \pm 7.6	209.6 ^c \pm 5.7
Serum IL-10 (pg/mL)	401 ^a \pm 7.6	401.8 ^a \pm 5.5	204.5 ^b \pm 8.5	306.1 ^c \pm 9.3	312 ^c \pm 8.1
IL-1 β /IL10 ratio	0.09 ^a	0.08 ^a	0.42 ^b	0.18 ^c	0.19 ^c
TNF- α /IL10 ratio	0.37 ^a	0.37 ^a	1.47 ^b	0.65 ^c	0.66 ^c

Values are means \pm SD for 6 different rats per treatment. Values with different letters are statistically different at $P < 0.05$. SD, standard deviation.

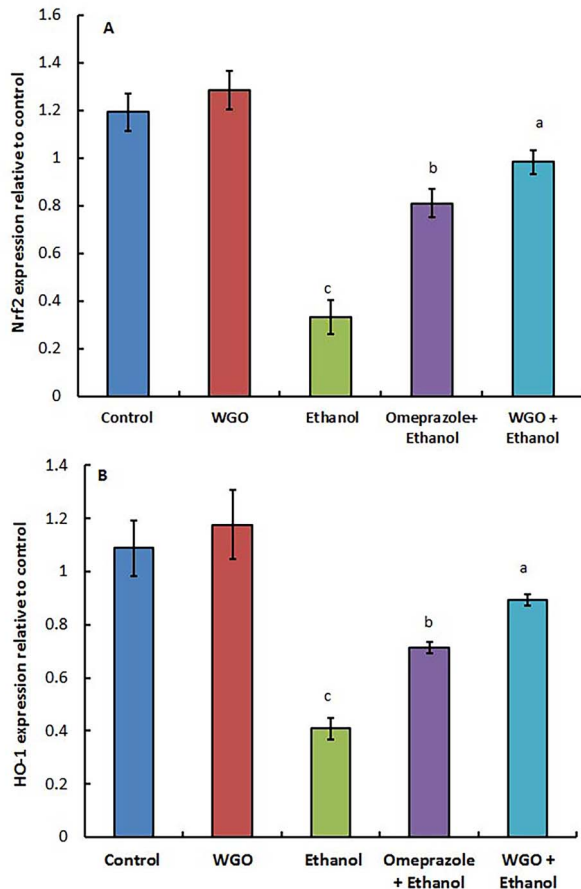


Fig. 2. Quantification of Nrf2 (A) and HO-1 (B) mRNA expression in rat gastric tissue. Values reported as means \pm SEM ($n = 6$). ANOVA test was followed by post hoc multiple comparisons test. Values with different letters are significant at $P < 0.05$.

(Fig. 5F). Conversely, WGO plus ethanol and omeprazole plus ethanol pretreated rats showed marked decrease in NF- κ B expression (Fig. 5D and E) with a substantial reduce in the average immune reactive stained area % (Fig. 5F).

In the stomach tissue of the control and WGO groups, TGF- β 1 expression (Fig. 6A and B) demonstrated that TGF- β 1 expression was regular (brown color). TGF- β 1 immunoreactivity in the control and WGO groups did not differ significantly (Fig. 6F). When ethanol-treated rats were compared to the control and WGO groups, they demonstrated a significant ($P < 0.05$) drop in TGF- β 1 expression (Fig. 6C), as well as a significant ($P < 0.05$) decline in the percentage of the immune reactive stained area (Fig. 6F). Pretreatment of ethanolic groups with

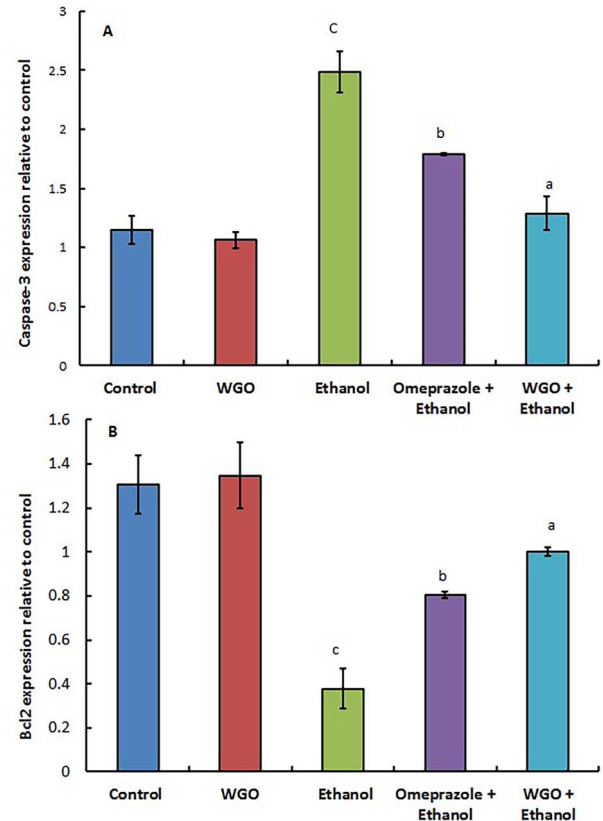


Fig. 3. Quantification of caspase-3 (A) and Bcl-2 (B) mRNA expression in rat stomach. Values are expressed as means \pm SEM ($n = 6$). ANOVA test was followed by post hoc multiple comparisons test. At $P < 0.05$, values with various letters are significant.

WGO and omeprazole exhibited a conspicuous increase in TGF- β 1 expression (Fig. 6D and E) with a substantial rise in the mean immune-stained area % (Fig. 6F).

4. Discussion

Alcohol has been demonstrated to have a significant effect in stomach mucosal damage and upper gastrointestinal hemorrhage in a number of investigations.^{38,39} Ethanol-stimulated gastric lesions are a frequent model for investigating the biology of stomach ulcers and the impact of various pharmaceuticals and natural therapies on gastroprotection.^{39,40} There have been no in vivo research on WGO's gastroprotective efficacy or the mechanism behind its gastric protection in mice with an ethanol-induced gastric ulcer. A stomach ulcer model

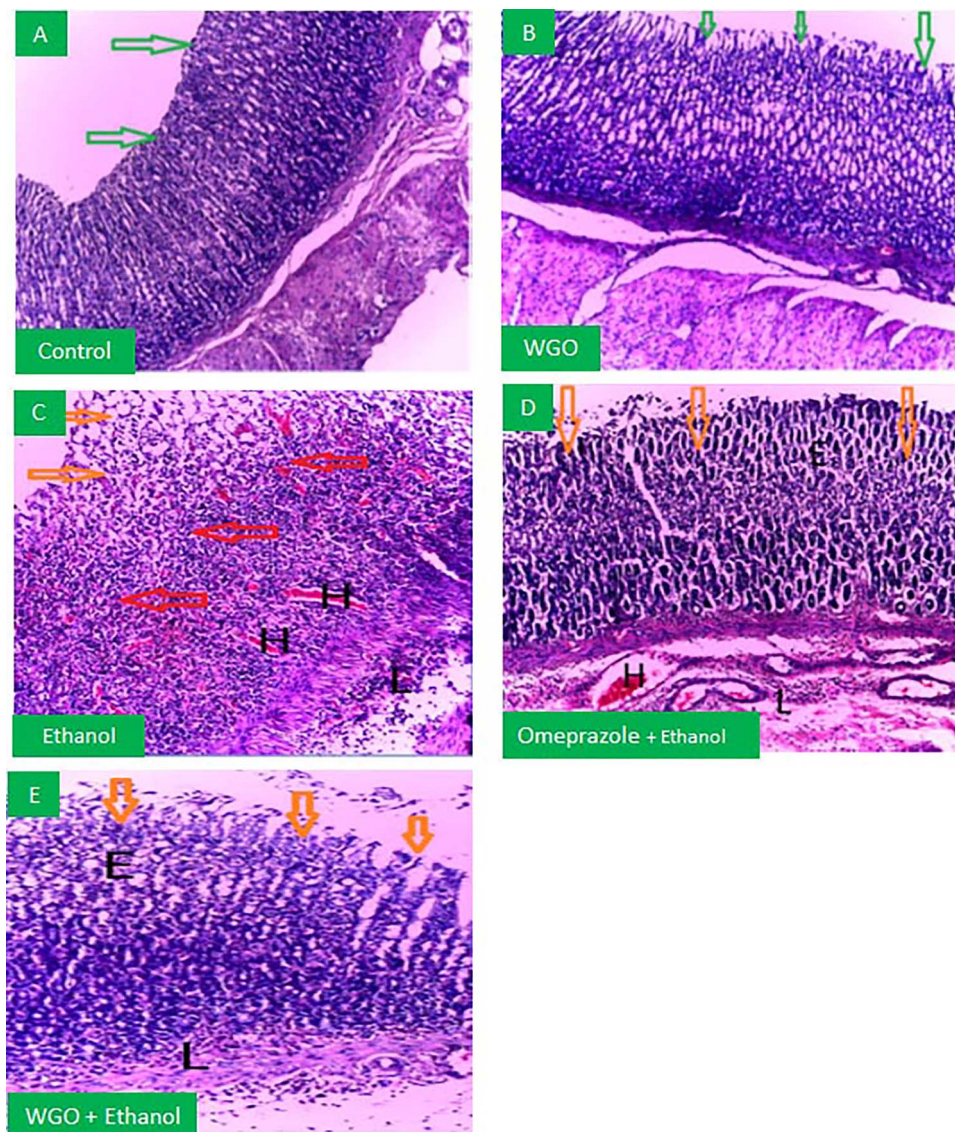


Fig. 4. Photomicrographs depicting a microscopic view of the gastrointestinal tissues of rats from the normal group (A), WGO group (B), ethanolic group (C), omeprazole + ethanol group (D), and WGO + ethanol group (E). Green arrows show healthy appearance of the coating structure and mucosal layer. The orange arrows indicate necrosis and degeneration at the mucosa's apex. Red arrows depict mucosal apoptosis and deterioration in the mucosa's depths. (E: edema, L: infiltration of inflammatory cells, H: hemorrhage) (H&E 100 \times).

caused by 80% ethanol (5 mL/kg) was developed in this study. The ethanol-induced stomach ulcer experimental model is valuable identifying the anti-ulcer potential of drugs and the likely mechanisms involved in this procedure⁴¹⁻⁴³. Two mechanisms by which ethanol induces stomach injury include dehydration, which degrades mucosal cell barriers, and cytotoxicity. This encourages the enlistment of ROS, producing leukocytes and inflammatory cytokines, all of which can result in cell death. Surprisingly, NF- κ B appears to be a key player in connecting these 2 events.⁴⁴

We found in the current study significant increase in gastric lesions in gastric wall mucosa, gastric volume, and GUI in ethanolic nontreated rats. We and others^{25,40,45} confirmed macroscopic lesions induced by ethanol. The considerable rise in GUI demonstrates

ethanol's powerful ulcerogenic effect, which is in line with prior research.⁴⁶ WGO pretreatment declined gastric lesions in the stomach wall mucosa, gastric juice volume level, GUI, and preventative index with an increase in gastric pH (PI). The considerable decrease in GUI and increased PI in WGO-treated rats imply a robust antiulcerogenic potential equivalent to that of omeprazole, a well-known antiulcer drug. The ulcerated tissues of the ethanolic nontreated group showed widespread degradation and necrosis of mucosal tissue, infiltration of leukocyte cells, edema, and severe bleeding, as previously reported.^{25,47,48} Nevertheless, WGO pretreated rats showed that mucosal damage was reduced, as was submucosal edema and inflammatory cell infiltration compared to omeprazole findings as reported here and by others.²⁴

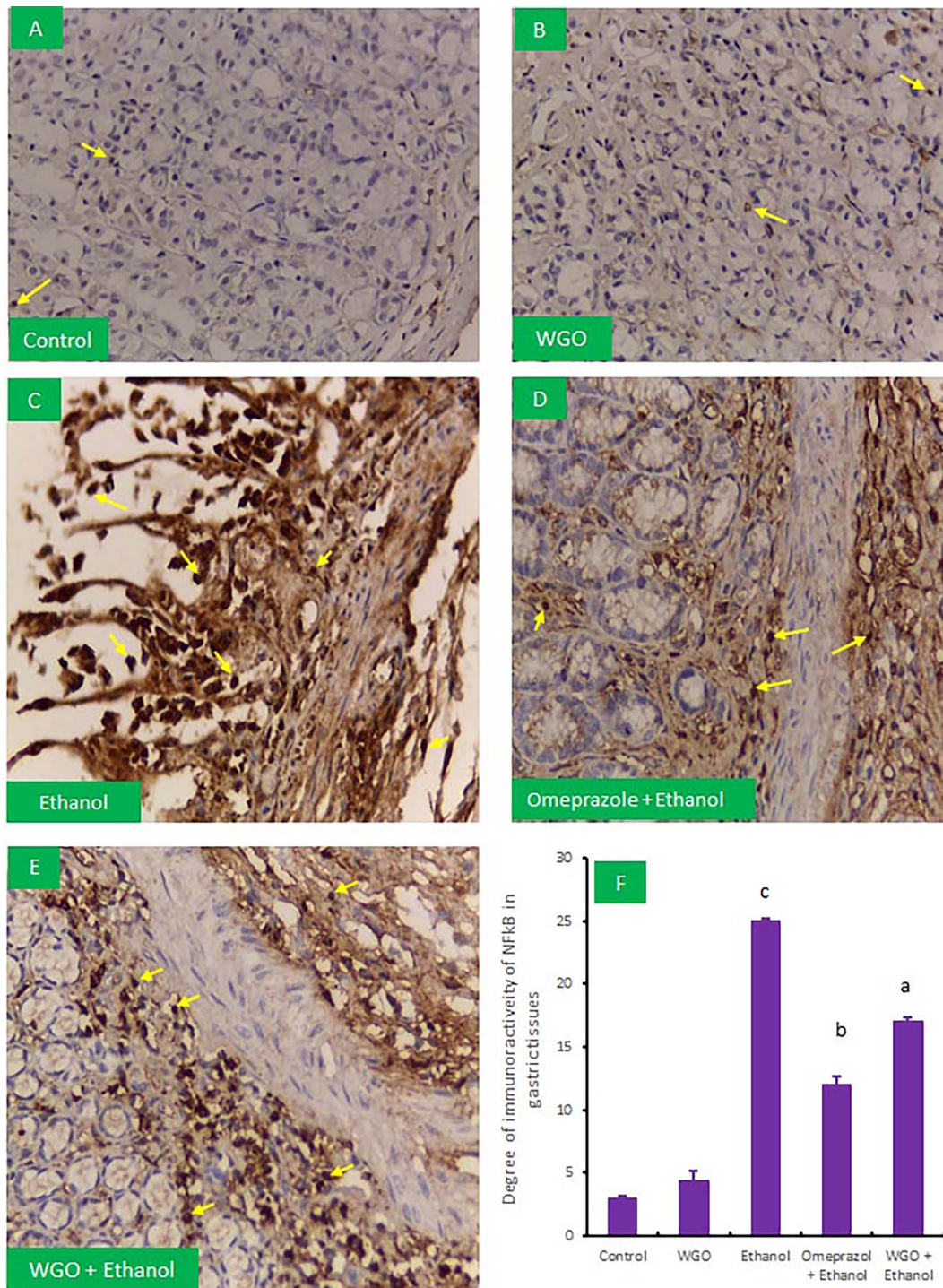


Fig. 5. Representative photomicrographs showing Immunohistochemical staining of nuclear factor kappa beta (NF-kB) in the experimental rats' gastric tissues (IHC, 400 \times). Immunopositive areas are expressed as nuclear expression of brown rounded nuclei (yellow arrows). A control group (A) and WGO treatment group (B) showed normal expression of NF-kB. The ethanolic group (C) showed more expression. The omeprazole + ethanol treated group (D), and a WGO + ethanol treated group (E) showed restoration in NF-kB expression. (F) Quantification of NF-kB expression. The area percent (%) of NF-kB immunohistochemical staining in 10 separate fields/sections was calculated, $n = 6$ rat/group. All the values in F are expressed as means + SD and areas of expression with different letters are significant at $P < 0.05$.

WGO pretreated to ethanolic rats regulated the production and expression of some oxidative stress markers such as NO, lipid peroxidation marker (MDA), antioxidant enzymes, apoptotic, antiapoptotic gene expressions, and the Nrf2/HO-1 expression. Gastric NO preserves the healing of gastric ulcers and the

integrity of the stomach mucosa wall defensive barrier.⁴⁹ NO protective effects are linked to the activation of the stomach mucosa and the creation of bicarbonate, which aids in the maintenance of gastric capillary blood supply, as well as inflammation inhibition.^{49,50} Reduced gastric NO is one of the major causes of gastric

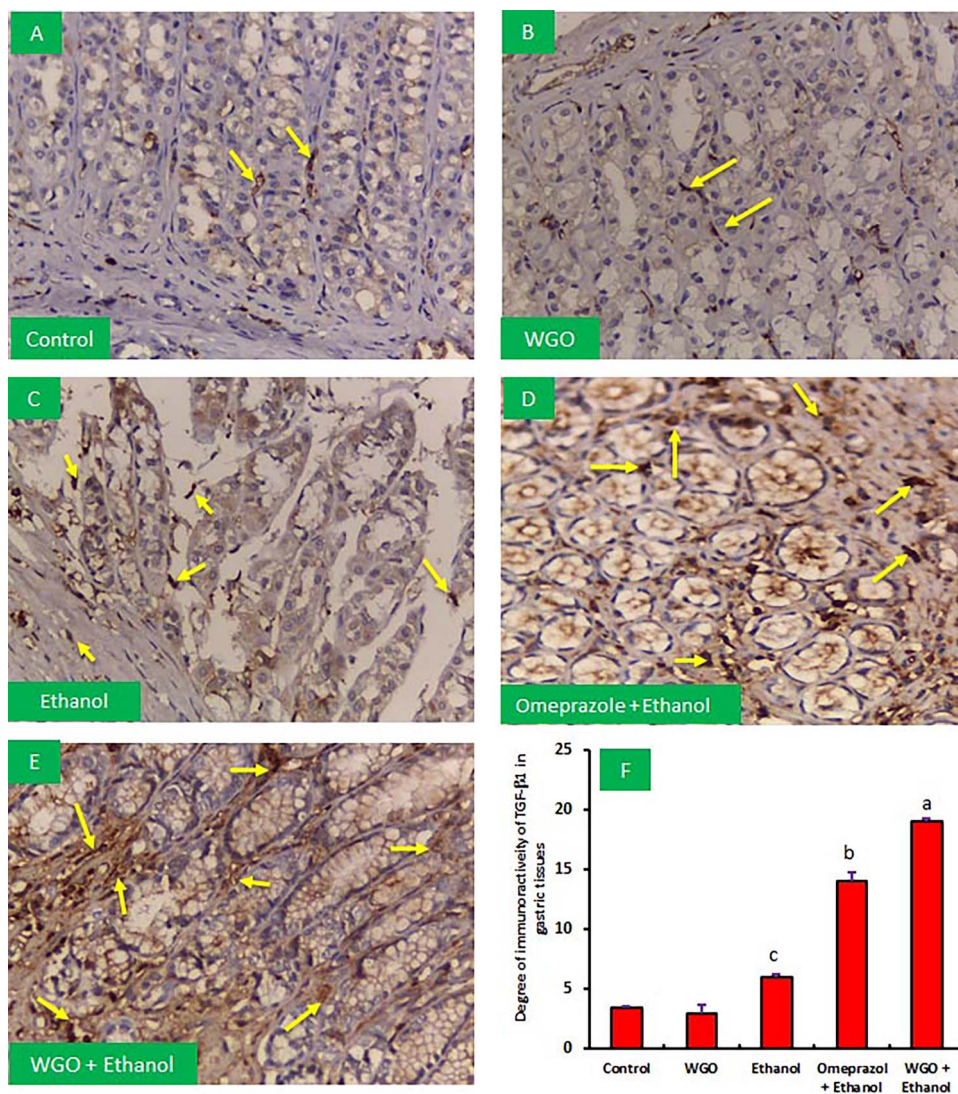


Fig. 6. Immunohistochemical staining for transforming growth factor $\beta 1$ (TGF- $\beta 1$, IHC, 400 \times) in ethanol-administered rats and possible protection by WGO. Immunopositive areas are brown colors (yellow arrows). A control group (A), WGO group (B), ethanolic group (C), omeprazole + ethanol treated group (D), and (E) WGO + ethanol treated group. (F) Quantification of TGF- $\beta 1$ term, the area percent (%) of TGF- $\beta 1$ immunohistochemistry staining was determined across 10 distinct fields/sections, $n = 6$ rat/group. The mean + SD is used to express all of the data. All the values in F are expressed as means + SD.

ulcers in the gastric mucosa.⁵¹ We found that ethanol-induced ulcerated rats had a lower level of gastric NO in the stomach mucosa, which is consistent with earlier reports.^{51,52} Pretreatment with WGO or omeprazole dramatically elevated stomach NO levels.

There is a well-established link between inflammation and ethanol-induced stomach ulcer damage.^{53,54} Ethanol triggers an inflammatory response in macrophages, causing them to release large levels of pro-inflammatory cytokines such as IL-1, IL-6, and TNF- α , which encourage the number of neutrophils present at the inflammatory area, causing the mucosal barrier to be destroyed.^{53,55} The quantity of free radicals produced by oxygen in the body was increased by these pro-inflammatory cytokines, allowing peptic ulcers to form more easily. Our findings, as well as those of others^{47,56}, are incorporated with this assumption. In

addition, ethanol exposure resulted in a considerable reduction in IL-10 production. Pretreatment with WGO or omeprazole resulted in a considerable drop in serum TNF- α and IL-1 β levels, as well as a considerable increase in IL-10, indicating anti-inflammatory impact for WGO. WGO has been shown to have an anti-inflammatory impact on rat liver toxicity.⁵⁷ This effect could be due to WGO's high content of unsaturated fatty acids (81%) that have anti-inflammatory properties and the ability to reduce oxygen-free radicals.⁵⁸

The pathogenic development of gastric ulcer has been connected to oxidative stress.⁴⁷ The current study found that in ethanolic nontreated rats, the redox balance is disrupted, worsen by lipid peroxidation, and antioxidant enzymes are depleted (GSH and CAT). MDA levels rose as a result of a rise in superoxide radical anions (O₂⁻) and ROS, as well as a depletion of antioxidant

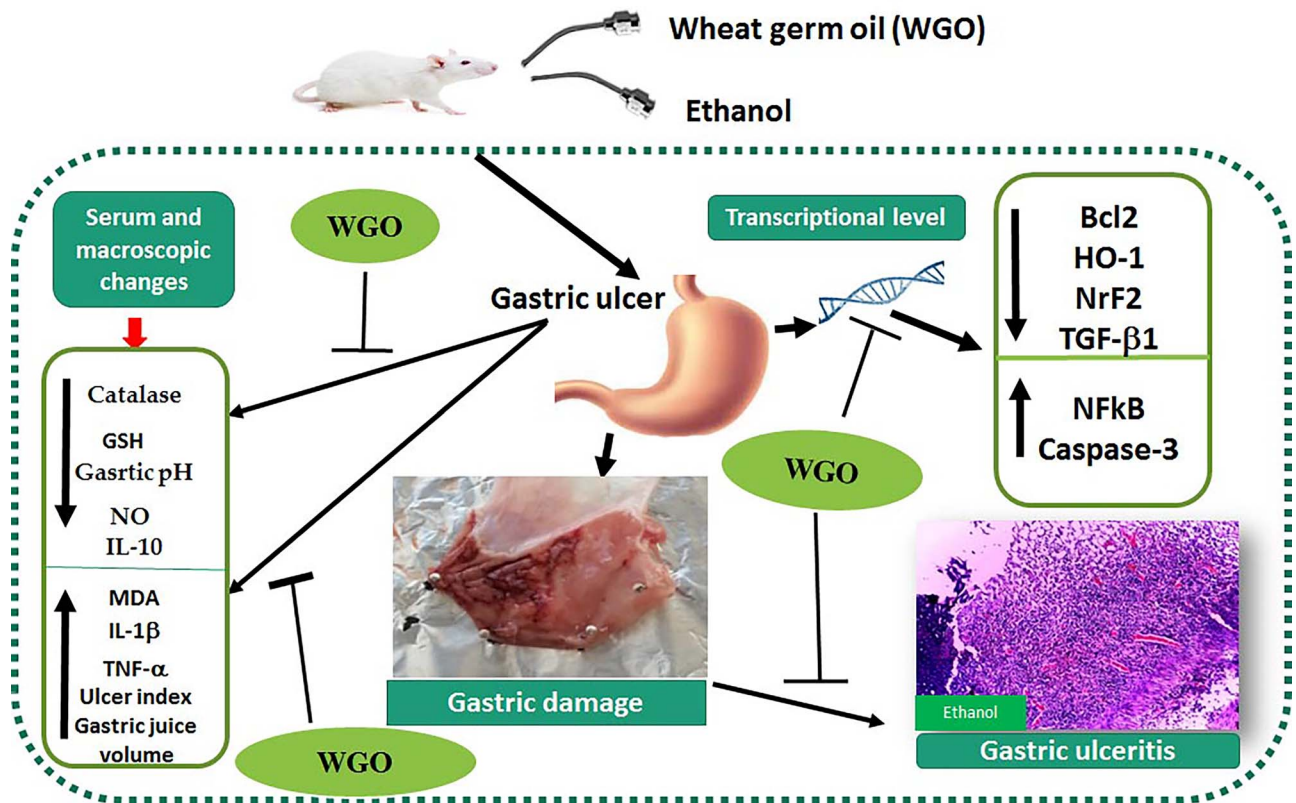


Fig. 7. The collective preventive impacts of WGO against ethanol-induced stomach ulcers in rats.

enzymes.⁵⁹ These findings are in line with previous research.^{47,48,60} In contrast to ethanolic nontreated rats, WGO and omeprazole pretreatment resulted in significant increases in GSH and CAT serum levels, as well as a reduction in both serum and tissue levels of MDA; WGO exhibits gastroprotective qualities against acute ethanol-induced GUs, showing its antioxidant activity. In a similar study, WGO was found to have potent antioxidant properties in mice with aspirin-induced gastrotoxicity.²⁴

The intrinsic mitochondrial pathway triggers apoptosis in the intestinal mucosa in response to oxidative stress and inflammatory cytokines. The antiapoptotic Bcl2 and proapoptotic Bax and caspase-3 proteins control oxidative stress-induced apoptosis, following ethanol intubation, contributing to the breakdown of gastric mucosal wall integrity.^{37,61} Apoptosis is inhibited by downregulation of apoptotic proteins (Bax and caspase-3) and overexpression of Bcl2 expression, which slows the healing of gastric lesions.^{40,61} The data obtained from our study reveal that WGO and omeprazole pretreated substantially upregulated Bcl2 with downregulation of caspase-3 mRNA gene expression relative to ethanolic nontreated rats. Our findings show that WGO pretreatment decreases stomach mucosal apoptosis. These findings are in parallel with earlier research, which documented that WGO has an antiapoptotic effect in CCL4-induced nephrotoxicity.⁶²

By replenishing natural antioxidant enzymes (GSH, CAT, and HO-1), the Nrf2/HO-1 signaling pathway

protects cells from damage caused by oxidative stress.^{55,63} In the cytoplasm, Nrf2 connects to the negative regulator Keap1 and becomes inactive. Nrf2 is dissociated from Keap1 by oxidative stress, which enhances that phase II enzymes are activated due to their transfer from the cytoplasm to the nucleus.⁵² HO-1 has been related to apoptosis prevention and cytoprotection against oxidative stress.^{25,52,63} In this investigation, the ethanolic nontreated group showed downregulation of Nrf2 and HO-1, but the WGO and omeprazole pretreatment groups showed overexpression of Nrf2/HO-1 mRNA gene, which is consistent with earlier findings.^{47,48}

The Nrf2/HO-1 pathway is a critical redox mechanism linked to oxidative stress and the production of NF-kB.^{64,65} NF-kB is a crucial pro-inflammatory cytokines regulator. By enhancing inflammatory cytokines, decreased expression of Nrf2 leads to an increase in the production of ROS and an increase in inflammation.^{66,67} NF-kB is elevated in response to oxidative stress and downregulates Nrf2 expression, increasing the ROS and elevating inflammation through enhancing inflammatory cytokines. Nrf2 inhibits NF-kB, which reduces pro-inflammatory cytokine transmission while also activating antioxidant defenses.^{63,68} Antioxidants have previously been shown to decrease NF-kB activation induced by ROS and to suppress the production of numerous inflammatory cytokines. Using immunohistochemistry analysis, we found that NF-kB is enhanced in ethanolic nontreated rats, as reported by others.^{25,48,56}

WGO showed that NF- κ B expression was downregulated, which might be related to WGO's ROS-scavenging action. This is the first study to show that WGO decreases apoptosis and suppresses NF- κ B in an ethanol-induced GU model.

TGF- β 1 is a key growth factor that has a healing impact on the GU by inducing cell migration and enhanced vascular proliferation, resulting in increased extracellular matrix deposition.⁶⁹ TGF- β 1 may limit cell proliferation in a number of cells; however, it can also promote angiogenesis⁷⁰, which is largely involved in the production of VEGF, and it is responsible for developing extracellular matrix components that perform an important role in tissue regeneration and wound healing.⁷¹ TGF's strong immunoreactivity boosted epithelial cell proliferation in gastric glands.⁷² We found a substantial decrease in TGF-1 expression in the stomach of ethanolic nontreated rats, but a significant rise in WGO treatment rats. According to this discovery, high TGF- β 1 term is a part of the normal healing response of stomach tissue in WGO therapy rats.^{37,69}

As discussed previously, WGO showed anti-inflammatory and antioxidant impacts.²¹ It has essential polyunsaturated fatty acids, such as linoleic and linolenic acids and vitamin E, that have an antioxidative stress effect.²² WGO has activity against liver disease; it was found that WGO has the ability to protect against oxidative stress and hepatotoxicity induced by the immunosuppressive agent (cyclosporine A) and benzene.⁷³ Current findings added new role for WGO against ethanol-induced gastric ulcer through the regulation of different cytokines, apoptosis, and fibrosis-associated genes.

In short, this study confirmed the clinical relevance of usage WGO as a natural therapy can be used safely to antagonize the adverse effects of ethanol against gastric ulcer through the regulation of anti-inflammatory, anti-apoptotic, and antioxidant activities.

5. Conclusion

WGO protected rats from ethanol-induced stomach ulcers by lowering oxidative stress indicators and inflammatory markers. WGO restored the reduction in IL-1 and TNF cytokines and decreased gastric volume and GUI, while increased PGI. WGO upregulated Nrf2-mediated HO-1 and stimulated the anti-inflammatory pathways through the downregulation of NF- κ B and upregulation of IL-10, TGF- β 1, and apoptotic/antiapoptotic-related genes. The collective impacts induced by WGO against ethanol-induced gastric ulcer and toxicity are shown in Fig. 7.

Acknowledgments

We appreciate the financial assistance from Taif University Researchers Supporting Project (TURSP-2020/09) from Taif University in Taif, Saudi Arabia.

Funding

The Researchers Support Project (TURSP-2020/09) of Taif University, Taif, Saudi Arabia, provided the fund for this research.

Conflict of interest statement. The author asserts that they have no potential conflict of interest.

Data availability statement

Current data are available upon request.

Ethical approval and statement

The National Institutes of Health guidelines for the care and use of laboratory animals were followed in this investigation for project TURSP-2020-09. To keep the experimental animals safe, all precautions were taken.

Authors' contributions

All authors contributed equally to this study.

References

1. Chaturvedi A, et al. Effect of ethanolic extract of *Eugenia jambolana* seeds on gastric ulceration and secretion in rats. *Indian J Physiol Pharmacol.* 2007;**51**(2):131.
2. Mentis A, Lehours P, Mégraud F. Epidemiology and diagnosis of *Helicobacter pylori* infection. *Helicobacter.* 2015;**20**:1–7.
3. Laine L, Takeuchi K, Tarnawski A. Gastric mucosal defense and cytoprotection: bench to bedside. *Gastroenterology.* 2008;**135**(1): 41–60.
4. Groenen MJ, et al. Incidence of duodenal ulcers and gastric ulcers in a western population: back to where it started. *Can J Gastroenterol.* 2009;**23**(9):604–608.
5. de Lira Mota KS, et al. Flavonoids with gastroprotective activity. *Molecules.* 2009;**14**(3):979–1012.
6. Liu P, et al. Alcohol intake and stroke in eastern Asian men: a systemic review and meta-analysis of 17 prospective cohort studies. *Zhonghua Yi Xue Za Zhi.* 2010;**90**(40):2834–2838.
7. Chen Y, et al. Inhibitory effect of flavonoid extract of lotus leaf on alcohol-induced gastric injury by antioxidant capacity in mice. *J Food Qual.* 2020;**2020**:1206247.
8. Knoll M, et al. Action of pure ethanol and some alcoholic beverages on the gastric mucosa in healthy humans: a descriptive endoscopic study. *Endoscopy.* 1998;**30**(03):293–301.
9. Lahiri S, Palit G. An overview of the current methodologies used for evaluation of gastric and duodenal anti-ulcer agents. *Pharmacologia.* 2012;**3**:249–257.
10. Adinortey M, et al. In vivo models used for evaluation of potential antigastroduodenal ulcer agents. *Ulcers.* 2013;**2013**:796405 <https://doi.org/10.1155/2013/796405>.
11. Liang J, et al. Prophylactic efficacy of patchoulene epoxide against ethanol-induced gastric ulcer in rats: influence on oxidative stress, inflammation and apoptosis. *Chem Biol Interact.* 2018;**283**:30–37.
12. Kuna L, et al. Peptic ulcer disease: a brief review of conventional therapy and herbal treatment options. *J Clin Med.* 2019;**8**(2):179. doi: 10.3390/jcm8020179.

13. Bighetti AE, et al. Antiulcerogenic activity of a crude hydroalcoholic extract and coumarin isolated from *Mikania laevigata* Schultz Bip. *Phytomedicine*. 2005;**12**(1–2):72–77.
14. Lakshmi V, et al. Gedunin and photogedunin of *Xylocarpus granatum* show significant anti-secretory effects and protect the gastric mucosa of peptic ulcer in rats. *Phytomedicine*. 2010;**17**(8–9):569–574.
15. Chanda S, Baravalia Y, Kaneria M. Protective effect of *Polyalthia longifolia* var. *pendula* leaves on ethanol and ethanol/HCl induced ulcer in rats and its antimicrobial potency. *Asian Pac J Trop Med*. 2011;**4**(9):673–679.
16. Boutemine IM, et al. Gastro-protective, therapeutic and anti-inflammatory activities of *Pistacia lentiscus* L. fatty oil against ethanol-induced gastric ulcers in rats. *J Ethnopharmacol*. 2018;**224**:273–282.
17. Boutemine IM, et al. Beneficial role of *Pistacia lentiscus* aqueous extract in experimental colitis: anti-inflammatory and potential therapeutic effects. *Inflammopharmacology*. 2021;**29**(4):1225–1239.
18. Jensen MK, et al. Intakes of whole grains, bran, and germ and the risk of coronary heart disease in men. *Am J Clin Nutr*. 2004;**80**(6):1492–1499.
19. Liu RH. Whole grain phytochemicals and health. *J Cereal Sci*. 2007;**46**(3):207–219.
20. Zhu KX, Zhou HM, Qian HF. Proteins extracted from defatted wheat germ: nutritional and structural properties. *Cereal Chem*. 2006;**83**(1):69–75.
21. Niu L-Y, Jiang S-T, Pan L-J. Preparation and evaluation of antioxidant activities of peptides obtained from defatted wheat germ by fermentation. *J Food Sci Technol*. 2013;**50**(1):53–61.
22. Mohamed DA, Ismael AI, Ibrahim AR. Studying the anti-inflammatory and biochemical effects of wheat germ oil. *Deutsche Lebensmittel-Rundschau*. 2005;**101**(2):66–72.
23. Saleh ZA, et al. Effect of carrot and wheat germ oil supplementation on antioxidant status of rats exposed to benzene. *Pol J Food Nutr Sci*. 2010;**60**(2):175–181.
24. Mohamed HRH, Hamad SR. Nullification of aspirin induced gastrototoxicity and hepatotoxicity by prior administration of wheat germ oil in *Mus musculus*: histopathological, ultrastructural and molecular studies. *Cell Mol Biol (Noisy-le-grand)*. 2017;**63**(8):120–130.
25. Rahman Z, Dwivedi DK, Jena GB. Ethanol-induced gastric ulcer in rats and intervention of tert-butylhydroquinone: involvement of Nrf2/HO-1 signalling pathway. *Hum Exp Toxicol*. 2020;**39**(4):547–562.
26. Qin S, et al. Astragaloside IV protects ethanol-induced gastric mucosal injury by preventing mitochondrial oxidative stress and the activation of mitochondrial pathway apoptosis in rats. *Front Pharmacol*. 2019;**10**:894.
27. Mousa AM, et al. Antiulcerogenic effect of *Cuphea ignea* extract against ethanol-induced gastric ulcer in rats. *BMC Complement Altern Med*. 2019;**19**(1):345.
28. Beiranvand M, Bahramikia S. Ameliorating and protective effects mesalazine on ethanol-induced gastric ulcers in experimental rats. *Eur J Pharmacol*. 2020;**888**:173573.
29. Saremi K, et al. Gastroprotective activity of a novel Schiff base derived dibromo substituted compound against ethanol-induced acute gastric lesions in rats. *BMC Pharmacol Toxicol*. 2019;**20**(1):13.
30. Takagi K, Okabe S. The effects of drugs on the production and recovery processes of the stress ulcer. *Jpn J Pharmacol*. 1968;**18**(1): 9–18.
31. AbdulSalam H, Kha H. Potential antioxidant, anti-inflammatory and gastroprotective effect of grape seed extract in indomethacin-induced gastric ulcer in rats. *Int J Pharmacol*. 2019;**15**:209–218.
32. Atak Yucel A, et al. Comparison of two different applications of the Griess method for nitric oxide measurement. *J Exp Integr Med*. 2012;**2**:1.
33. Lefèvre G, et al. Evaluation of lipid peroxidation by measuring thiobarbituric acid reactive substances. *Ann Biol Clin (Paris)*. 1998;**56**(3):305–319.
34. Pfaffl MW. A new mathematical model for relative quantification in real-time RT-PCR. *Nucleic Acids Res*. 2001;**29**(9):e45.
35. Sistani Karampour N, et al. Gastroprotective effects of Betanin against ethanol-induced gastric ulcer in rats. *Jundishapur J Nat Pharm Prod*. 2019: <https://brief.land/jjnpp/articles/14473.html>.
36. Dwivedi DK, Jena GB. Glibenclamide protects against thioacetamide-induced hepatic damage in Wistar rat: investigation on NLRP3, MMP-2, and stellate cell activation. *Naunyn Schmiedeberg's Arch Pharmacol*. 2018;**391**(11):1257–1274.
37. Liu H, et al. Role of transforming growth factor β 1 in the inhibition of gastric cancer cell proliferation by melatonin in vitro and in vivo. *Oncol Rep*. 2019;**42**(2):753–762.
38. Franke A, Teyssen S, Singer MV. Alcohol-related diseases of the esophagus and stomach. *Dig Dis*. 2005;**23**(3–4):204–213.
39. Simões S, et al. Animal models of acute gastric mucosal injury: macroscopic and microscopic evaluation. *Anim Model Exp Med*. 2019;**2**(2):121–126.
40. Aziz RS, et al. Oxyresveratrol ameliorates ethanol-induced gastric ulcer via downregulation of IL-6, TNF- α , NF- κ B, and COX-2 levels, and upregulation of TFF-2 levels. *Biomed Pharmacother*. 2019;**110**:554–560.
41. Li W, et al. Protective effect of tetrahydrocoptisine against ethanol-induced gastric ulcer in mice. *Toxicol Appl Pharmacol*. 2013;**272**(1):21–29.
42. Vijayakumar AR, et al. Ulcer protective activity of *Jatropha gossypifolia* Linn. in Wistar rats. *Pharm Res*. 2016;**8**(Suppl 1):S61–S66.
43. Sistani Karampour N, et al. Gastroprotective effect of Zingerone on ethanol-induced gastric ulcers in rats. *Medicina (Kaunas)*. 2019;**55**(3):64. doi: 10.3390/medicina55030064.
44. Kim JH, et al. Suppressive effect of astaxanthin isolated from the *Xanthophyllomyces dendrorhous* mutant on ethanol-induced gastric mucosal injury in rats. *Biosci Biotechnol Biochem*. 2005;**69**(7):1300–1305.
45. Fu Y, et al. Gastroprotective and anti-ulcer effects of oxymatrine against several gastric ulcer models in rats: possible roles of antioxidant, anti-inflammatory, and prosurvival mechanisms. *Phytother Res*. 2018;**32**(10):2047–2058.
46. Al Batran R, et al. In vivo antioxidant and antiulcer activity of *Parkia speciosa* ethanolic leaf extract against ethanol-induced gastric ulcer in rats. *PLoS One*. 2013;**8**(5): e64751.
47. Zhou D, et al. Gastroprotective effect of gallic acid against ethanol-induced gastric ulcer in rats: involvement of the Nrf2/HO-1 signaling and anti-apoptosis role. *Biomed Pharmacother*. 2020;**126**:110075.
48. Raish M, et al. Gastroprotective effect of sinapic acid on ethanol-induced gastric ulcers in rats: involvement of Nrf2/HO-1 and NF- κ B signaling and antiapoptotic role. *Front Pharmacol*. 2021;**12**:622815.
49. Sánchez-Mendoza ME, et al. Gastroprotection of calein D against ethanol-induced gastric lesions in mice: role of

- prostaglandins, nitric oxide and sulfhydryls. *Molecules*. 2019; **24**(3):622. doi: 10.3390/molecules24030622.
50. Tarnawski AS. Cellular and molecular mechanisms of gastrointestinal ulcer healing. *Dig Dis Sci*. 2005;**50**(Suppl 1):S24–S33.
 51. Sánchez S, et al. Role of prostaglandins and nitric oxide in gastric damage induced by metamizol in rats. *Inflamm Res*. 2002;**51**(8):385–392.
 52. Abdelwahab SI. Protective mechanism of gallic acid and its novel derivative against ethanol-induced gastric ulcerogenesis: involvement of immunomodulation markers, Hsp70 and Bcl-2-associated X protein. *Int Immunopharmacol*. 2013;**16**(2):296–305.
 53. Fahmy NM, et al. Gastroprotective effects of *Erythrina speciosa* (Fabaceae) leaves cultivated in Egypt against ethanol-induced gastric ulcer in rats. *J Ethnopharmacol*. 2020;**248**:112297.
 54. de Souza MC, Vieira AJ, Beserra FP, Pellizzon CH, Nóbrega RH, Rozza AL. Gastroprotective effect of limonene in rats: influence on oxidative stress, inflammation and gene expression. *Phytomedicine*. 2019;**53**:37–42.
 55. Badr AM, El-Orabi NF, Ali RA. The implication of the crosstalk of Nrf2 with NOXs, and HMGB1 in ethanol-induced gastric ulcer: potential protective effect is afforded by raspberry ketone. *PLoS One*. 2019;**14**(8):e0220548.
 56. Arab HH, Salama SA, Eid AH, Kabel AM, Shahin NN. Targeting MAPKs, NF- κ B, and PI3K/AKT pathways by methyl palmitate ameliorates ethanol-induced gastric mucosal injury in rats. *J Cell Physiol*. 2019;**234**(12):22424–22438.
 57. Ahmed A, Gad A, El-Raouf O. Investigations of the possible utility of wheat germ oil versus diclofenac sodium induced liver toxicity in rats. *Pharm Chem J*. 2019;**6**:38–45.
 58. Nagib R. Protective effect of wheat germ powder and oil on metabolic disturbances in rats. *J Food Dairy Sci*. 2018;**2018**:21–27.
 59. Ito M, et al. Anti-ulcer effects of antioxidants: effect of probucol. *Eur J Pharmacol*. 1998;**354**(2–3):189–196.
 60. Yoo JH, et al. Gastroprotective effects of fermented lotus root against ethanol/HCl-induced gastric mucosal acute toxicity in rats. *Nutrients*. 2020;**12**(3).
 61. He H, et al. Gastroprotective effect of araloside A on ethanol- and aspirin-induced gastric ulcer in mice: involvement of H(+)/K(+)-ATPase and mitochondrial-mediated signaling pathway. *J Nat Med*. 2019;**73**(2):339–352.
 62. El-Shorbagy H. Molecular and anti-oxidant effects of wheat germ oil on CCl 4-induced renal injury in mice ARTICLE INFO ABSTRACT. *J Appl Pharm Sci*. 2017;**7**:94–102.
 63. Yanaka A. Role of NRF2 in protection of the gastrointestinal tract against oxidative stress. *J Clin Biochem Nutr*. 2018;**63**(1):18–25.
 64. Sandireddy R, et al. Neuroinflammation and oxidative stress in diabetic neuropathy: futuristic strategies based on these targets. *Int J Endocrinol*. 2014;**2014**:674987.
 65. Zhang Y, et al. Alpha-boswellic acid protects against ethanol-induced gastric injury in rats: involvement of nuclear factor erythroid-2-related factor 2/heme oxygenase-1 pathway. *J Pharm Pharmacol*. 2016;**68**(4):514–522.
 66. Pan H, et al. The absence of Nrf2 enhances NF- κ B-dependent inflammation following scratch injury in mouse primary cultured astrocytes. *Mediat Inflamm*. 2012;**2012**:217580.
 67. Ganesh Yerra V, et al. Potential therapeutic effects of the simultaneous targeting of the Nrf2 and NF- κ B pathways in diabetic neuropathy. *Redox Biol*. 2013;**1**(1):394–397.
 68. Silva-Islas CA, Maldonado PD. Canonical and non-canonical mechanisms of Nrf2 activation. *Pharmacol Res*. 2018;**134**:92–99.
 69. Albaayit SF, et al. Prophylactic effects of *Clausena excavata* Burum. f. Leaf extract in ethanol-induced gastric ulcers. *Drug Des Devel Ther*. 2016;**10**:1973–1986.
 70. Sato T, et al. Vascular endothelial growth factor receptor 1 signaling facilitates gastric ulcer healing and angiogenesis through the upregulation of epidermal growth factor expression on VEGFR1+CXCR4 + cells recruited from bone marrow. *J Gastroenterol*. 2014;**49**(3):455–469.
 71. Polonikov AV, et al. Analysis of common transforming growth factor beta-1 gene polymorphisms in gastric and duodenal ulcer disease: pilot study. *J Gastroenterol Hepatol*. 2007;**22**(4):555–564.
 72. Antonisamy P, et al. Protective effects of friedelin isolated from *Azima tetracantha* Lam. against ethanol-induced gastric ulcer in rats and possible underlying mechanisms. *Eur J Pharmacol*. 2015;**750**:167–175.
 73. Durak I, Ozbek H, Elgün S. Cyclosporine reduces hepatic antioxidant capacity: protective roles of antioxidants. *Int Immunopharmacol*. 2004;**4**(3):469–473.